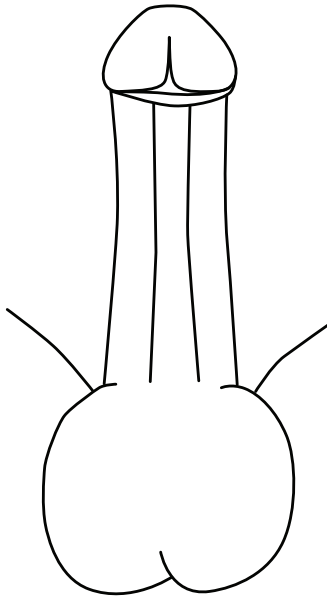
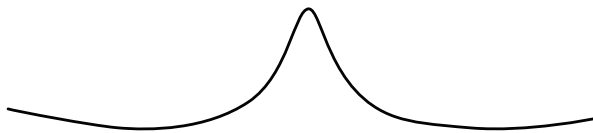


Anogenital Diagram—Male Sexual Organ and Anus

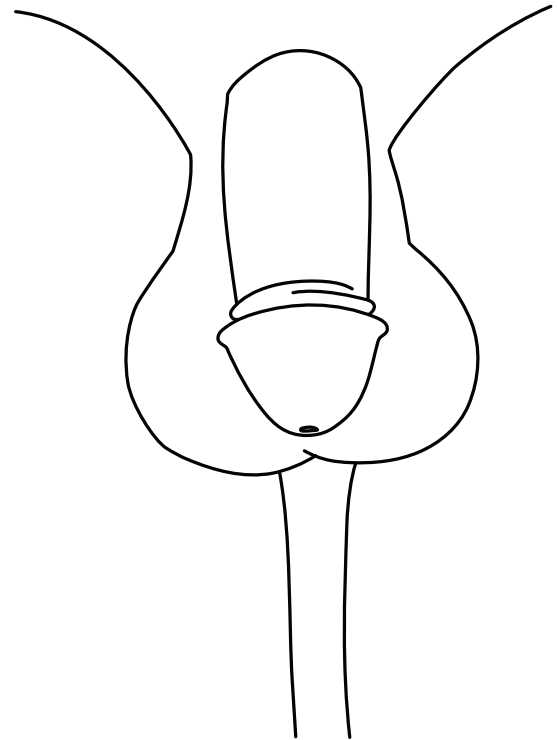
12



0



6



No injury noted Circumcised Uncircumcised

Page ____ of ____

Examiner's initials: _____

PATIENT LABEL OR

PATIENT'S NAME:

MRN#